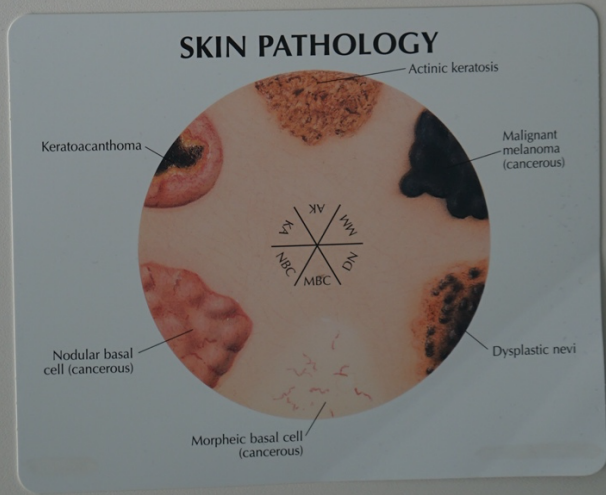
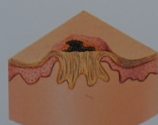
# Modell Hautpathologien

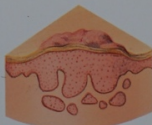



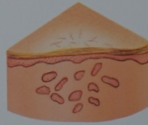## SKIN PATHOLOGY



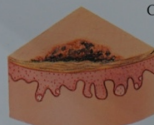Keratoacanthoma



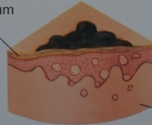Nodular basal cell (cancerous)



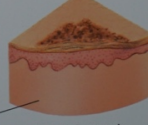
Morpheic basal cell (cancerous)



Dysplastic nevi



Malignant melanoma (cancerous)



Actinic keratosis

Corneum

Epidermis

Dermis